









# Management of the extraction socket and timing of implant placement: Consensus report and clinical recommendations of group 3 of the XV European Workshop in Periodontology

Maurizio S. Tonetti<sup>1,2</sup>  | Ronald E. Jung<sup>3</sup> | Gustavo Avila-Ortiz<sup>4</sup>  | Juan Blanco<sup>5</sup> | Jan Cosyn<sup>6</sup>  | Stefan Fickl<sup>7</sup> | Elena Figueroa<sup>8</sup> | Moshe Goldstein<sup>9</sup> | Filippo Graziani<sup>10</sup>  | Phoebus Madianos<sup>11</sup>  | Ana Molina<sup>8</sup> | Jose Nart<sup>12</sup> | Giovanni E. Salvi<sup>13</sup> | Ignacio Sanz-Martin<sup>8</sup>  | Daniel Thoma<sup>3</sup>  | Nele Van Assche<sup>14</sup> | Fabio Vignoletti<sup>8</sup> 

<sup>1</sup>Division of Periodontology and Implant Dentistry, Faculty of Dentistry, University of Hong Kong, Hong Kong, China

<sup>2</sup>European Research Group on Periodontology, Genova, Italy

<sup>3</sup>Clinic of Fixed and Removable Prosthodontics and Dental Material Science, University of Zurich, Zurich, Switzerland

<sup>4</sup>Department of Periodontics, The University of Iowa, Iowa City, Iowa

<sup>5</sup>Department of Surgery and Medical-Surgical Specialties (Dentistry area), Unit of Periodontology, University of Santiago de Compostela, Santiago, Spain

<sup>6</sup>Department of Dentistry, University of Ghent, Ghent, Belgium

<sup>7</sup>Division of Periodontology, University of Würzburg, Würzburg, Germany

<sup>8</sup>ETEP (Etiology and Therapy of Periodontal Diseases) Research Group, Department of Dental Clinic Specialties, Faculty of Dentistry, University Complutense, Madrid, Spain

<sup>9</sup>Department of Periodontology, Hebrew University, Jerusalem, Israel

<sup>10</sup>Sub-Unit of Periodontology, Halitosis and Periodontal Medicine, Department of Surgical, Medical and Molecular Pathology and Critical Care Medicine, University of Pisa, Pisa, Italy

<sup>11</sup>Department of Periodontology, Kapodistrian University, Athens, Greece

<sup>12</sup>Department of Periodontology, Universitat Internacional de Catalunya, Barcelona, Spain

<sup>13</sup>Department of Periodontology, School of Dental Medicine, University of Bern, Bern, Switzerland

<sup>14</sup>Private Practice of Periodontology and Implantology, Geel, Belgium

## Correspondence

Maurizio S. Tonetti, Periodontology, Faculty of Dentistry, Hong Kong University, Prince Philip Dental Hospital, 34 Hospital Road, Hong Kong, China.  
Email: tonetti@hku.hk

## Funding information

Funds for this workshop were provided by the European Federation of Periodontology in part through an unrestricted educational grant from Geistlich Pharma AG.

## Abstract

**Background:** The transition from a tooth requiring extraction to its replacement (with a dental implant) requires a series of clinical decisions related to timing, approach, materials, cost-effectiveness and the assessment of potential harm and patient preference. This workshop focused on the formulation of evidence-based consensus statements and clinical recommendations.

**Methods:** Four systematic reviews covering the areas of alveolar ridge preservation/bone grafting, immediate early and delayed implant placement and alveolar bone augmentation at the time of implant placement in a healed ridge formed the basis of the deliberations. The level of evidence supporting each consensus statement and its strength was described using a modification of the GRADE tool.

**Results:** The evidence base for each of the relevant topics was assessed and summarized in 23 consensus statements and 12 specific clinical recommendations. The

group emphasized that the evidence base mostly relates to single tooth extraction/replacement; hence, external validity/applicability to multiple extractions requires careful consideration. The group identified six considerations that should assist clinicians in clinical decision-making: presence of infection, inability to achieve primary stability in the restoratively driven position, presence of a damaged alveolus, periodontal phenotype, aesthetic demands and systemic conditions.

**Conclusions:** A substantial and expanding evidence base is available to assist clinicians with clinical decision-making related to the transition from a tooth requiring extraction to its replacement with a dental implant. More high-quality research is needed for the development of evidence-based clinical guidelines.

#### KEYWORDS

alveolar ridge preservation, bone grafting, clinical guidelines, dental implant, evidence-based dentistry, implant performance, implant placement/timing, implant survival, tooth extraction

## 1 | INTRODUCTION

The WHO oral health databank has shown important progress in tooth retention over a 20-year period (Kassebaum et al., 2014). Tooth extraction due to disease and/or trauma, however, remains a frequent occurrence leading to the indication of tooth replacement, such as an implant-supported fixed dental prosthesis.

It is important to underline that, in the vast majority of cases, dental extraction is indicated due to severe disease or trauma that has led to irreparable damage to the tooth and/or its supporting apparatus. Different clinical scenarios with varying extent and patterns of residual alveolar bone, therefore, may be encountered. Hence, a careful examination should be carried out before and immediately after tooth extraction in order to assess the applicability of different therapeutic strategies, which may involve implant placement.

Noteworthy, the decision to extract a tooth is intricately connected with thought processes related to its replacement, the assessment of the evidence pertaining to available treatment choices for both its retention and replacement, the cost-benefit profile of the available options and, ultimately, individual preferences of the patient and the treating clinician.

Following tooth extraction, a series of physiological changes affecting the alveolar bone that surrounds the extraction socket take place (Sculean, Stavropoulos, & Bosshardt, 2019). These include bone formation in the socket as well as volumetric resorption leading to changes in the dimensions and contours of the alveolar ridge. A previous meta-analysis found that average reductions of 3.87 mm (95% CI: -4.059 to -3.673) in the buccolingual ridge thickness and a vertical mid-buccal resorption of 1.67 mm (95% CI: -1.910 to -1.428) are to be expected following unassisted socket healing (van der Weijden, Dell'Acqua, & Slot, 2009). Attempts to limit bone resorption, shorten the overall treatment time and maximize therapeutic predictability have led to the development of five documented approaches that differ depending on variations in the management of

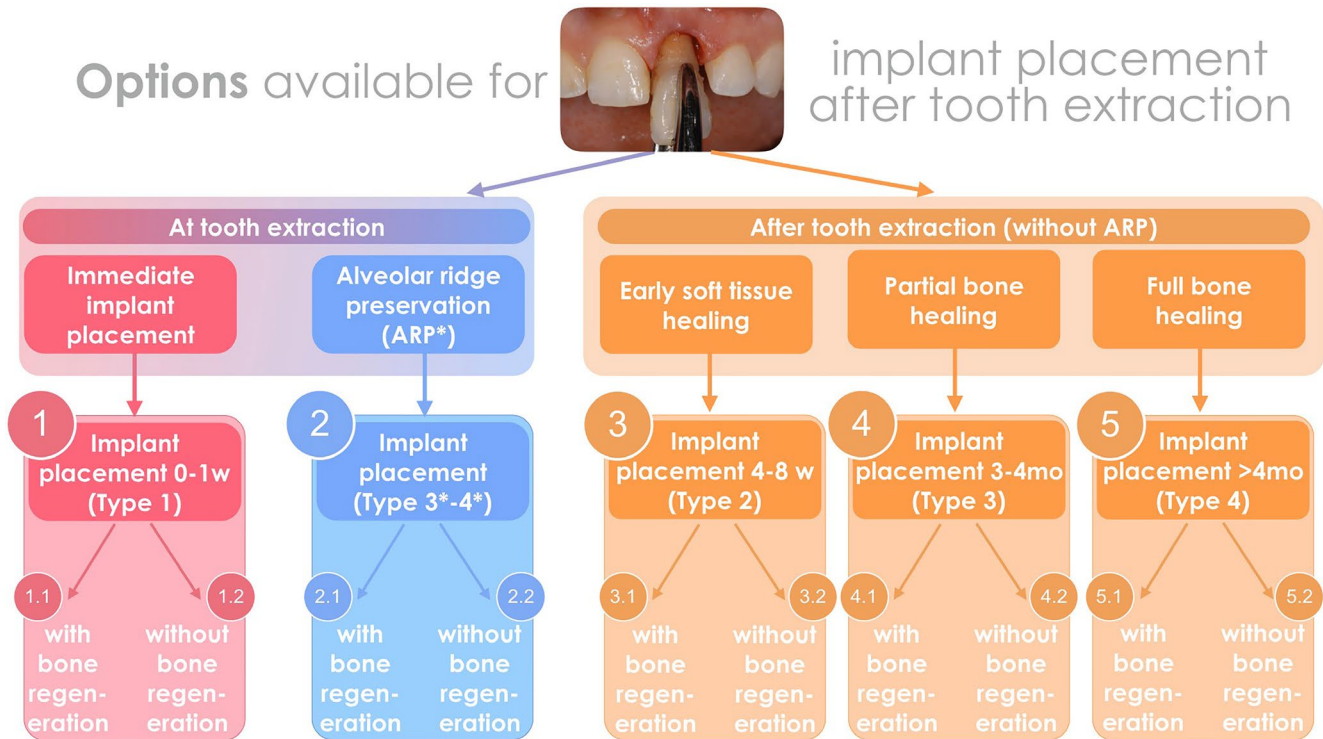
### Clinical Relevance

*Scientific rationale for the study:* Clinical decisions on how to best transition from a tooth requiring extraction to its implant replacement require the consideration of a wide range of evidence.

*Principal findings:* The discussions of this workshop were informed by four specifically commissioned systematic reviews. The evidence was graded, and consensus statements were formulated along with clinical recommendations. A substantial body of evidence is available to guide clinicians in making evidence-based decisions.

*Practical implications:* In their decision-making process, clinicians should pay particular attention to the presence of infection, inability to achieve primary stability of the implant in the restoratively driven position, presence of a damaged alveolus, periodontal phenotype, aesthetic demands and systemic conditions.





**FIGURE 1** Diagrammatic representation of the different options for implant replacement after tooth extraction. Please note the two procedures that are performed at the time of tooth extraction and the other three that are performed at a later time. ARP, alveolar ridge preservation. The figure illustrates the five different options, numbered 1–5, available after tooth extraction to transition towards an implant supported restoration. Two interventions, immediate implant placement and alveolar ridge preservation (ARP), are performed at the time of tooth extractions. Three additional options are available following different degrees of healing after the extraction: early soft tissue healing, partial bone healing and full bone healing. All options can theoretically be performed with or without the addition of bone regeneration. The figure also illustrates the four types of implant placement: type 1 (immediate, 0–1 week), type 2 (early, 4–8 weeks), type 3 (delayed, 3–4 months) and type 4 (standard placement in a healed ridge, >4 months). The diagram introduces type 3\* and type 4\* implant placement: this refers to implant placement in a ridge that has been preserved and the 3\* or 4\* classification refers to the duration of healing of the ARP procedure before implant placement. Please see text for additional details

the extraction site and the timing of implant placement. These approaches are illustrated in Figure 1 and include the following:

- A conventional treatment protocol involving tooth extraction and unassisted healing of the extraction site for a period of >16 weeks, followed by implant placement in a healed ridge. This approach has been termed type 4 implant placement.
- A conventional protocol modified by performing an interceptive procedure to minimize the dimensional changes that take place after tooth extraction, followed by implant placement 12–16 weeks later. This approach has been called alveolar ridge preservation (ARP), and it represents a modified type 3 or type 4 implant placement (further referred as Type 3\* or Type 4\* based on time of implant placement).
- An immediate implant placement protocol, characterized by implant placement at the time of or shortly after tooth extraction (<10 days after extraction), which is known as type 1 implant placement.
- An early implant placement protocol, characterized by implant placement after completion of the majority of soft tissue healing, but before the occurrence of complete bone maturation and ridge profile modification (4–8 weeks after tooth extraction, type 2 implant placement)
- A delayed implant placement protocol, characterized by implant placement after completion of soft tissue healing, and after the majority of the alveolar bone healing and profile and dimensional changes have taken place, which usually occurs at 12–16 weeks following tooth extraction. This has been termed as type 3 implant placement.

The different treatment modalities illustrated in Figure 1, which have been described in the literature and in the systematic reviews used as a basis for the deliberation at the workshop, are reflective of a variable degree of scientific and clinical validation (Gallucci, Hamilton, Zhou, Buser, & Chen, 2018). Accounting for different levels of validation is an important component of the background knowledge necessary for clinical decision-making.

In clinical practice, the choice between the aforementioned implant placement modalities has been empirically based on the assumption that the presence/absence of an intact residual ridge or socket walls is an indication for specific approaches. Evidence from comparative studies has, so far, played relatively little role in clinical decision-making processes. This group of the workshop focused on summarizing the scientific evidence in specific consensus statements and on providing

clinical recommendations relevant to these therapeutic alternatives. Table 1 illustrates the modified GRADE criteria used to describe the level of available evidence and the strength of the statements/clinical recommendations (Guyatt et al., 2011; Tonetti & Jepsen, 2014).

## 2 | EFFECT OF ALVEOLAR RIDGE PRESERVATION INTERVENTIONS FOLLOWING TOOTH EXTRACTION: A SYSTEMATIC REVIEW AND META-ANALYSIS

### 2.1 | Preamble

Tooth extraction triggers a sequence of biologic events that typically result in the horizontal and vertical reduction in alveolar ridge dimensions, and subsequent changes in its profile, which may interfere with further therapy. ARP is frequently indicated to attenuate these physiologic dimensional changes (Avila-Ortiz, Chambrone, & Vignoletti, 2019).

The aim of this systematic review was to critically analyse the available evidence on the effect of different modalities of ARP as compared to tooth extraction alone. ARP interventions were defined as filling the socket with a biomaterial (Alveolar ridge preservation via socket grafting [ARP-SG]), socket sealing (SS) through the sole application of a barrier material (autogenous or exogenous) or a combination of both, either involving primary intention healing following flap advancement or secondary intention healing. Outcomes were organized in three main categories: clinical, radiographic and patient-reported outcome measures (PROMs).

The systematic review included 25 articles from a total of 22 RCTs.

Sufficient data were available to perform 18 meta-analyses comparing five different ARP-SG treatment modalities to the control (unassisted socket healing).

Potential limitations of this systematic review are the low number of studies included in some of the subcategory meta-analyses

**TABLE 1** Specific modified GRADE criteria used to describe the level of evidence and the strength of a clinical statement

Level of evidence	Definition criteria
Level 1	Systematic review with meta-analysis
Level 2	Systematic review without meta-analysis, single multicenter RCT, multiple RCTs
Level 3	Single RCT, RCTs designed for different reason
Level 4	Case series, CCTs
Level 5	Expert opinion
Strength of statement	Definition criteria
High	High level of confidence: low risk of bias, adequate number of subjects and trials, negligible heterogeneity
Moderate	Good confidence, some risk of bias, heterogeneity, adequate number of subjects and trials
Low	Not confident, high risk of bias, uncertainty

and that none of the RCTs exhibited a low risk of bias, which calls for caution when interpreting these findings. Due to the high degree of clinical heterogeneity that exists between the majority of trials included, the conduction of a network meta-analysis was not justified.

### 2.2 | External validity of the findings

The statements on ARP-SG in this consensus report are primarily applicable to adults who require a single extraction in tooth-bound sites that exhibit substantial socket wall integrity after extraction, regardless of smoking status. Reasons for extraction may include catastrophic tooth fractures, extensive caries and endodontic failure. A word of caution is needed with regard to tooth loss due to severe periodontitis, as very limited residual bony walls may be available for worthwhile ridge preservation.

### 2.3 | Consensus statements

#### 2.3.1 | What is the effect of alveolar ridge preservation via socket grafting on ridge dimensions?

Alveolar ridge preservation via socket grafting attenuates the physiological bone dimensional changes that typically follow tooth extraction.

(Evidence Level 1: systematic review of RCTs, 18 RCTs and 612 subjects)—(Strength of statement: high).

Alveolar ridge preservation via socket grafting may prevent 1.5–2.4 mm of horizontal, 1–2.5 mm of vertical mid-buccal and 0.8–1.5 mm of mid-lingual vertical bone resorption as compared to tooth extraction alone.

(Evidence Level 1: meta-analysis of systematic review of RCTs, 14 RCTs and 676 subjects). (Strength of statement: high).

#### 2.3.2 | How do different alveolar ridge preservation modalities compare in terms of their effect on ridge dimensions?

In spite of the presence of multiple studies comparing a variety of bone grafts and SS approaches, it was not possible to identify an ARP approach associated with superior outcomes. This finding does not imply that any bone grafting and/or SS material unfailingly brings a therapeutic benefit, as only few materials are appropriately documented. The reader is referred to the original systematic review for a detailed compilation of the evidence for individual ARP treatment modalities and grafting materials.

(Evidence Level 2: systematic review without network meta-analysis, 22 RCTs and 730 subjects)—(Strength of statement: moderate).

#### 2.3.3 | What is the impact of buccal bone thickness on dimensional changes?

Sites presenting a thick buccal bone (e.g. >1.0–1.5 mm) exhibit less alveolar ridge dimensional changes after tooth extraction. It has also

been observed that the application of ARP-SG is more beneficial in sites exhibiting thin buccal bone.

(Evidence Level 2: systematic review without meta-analysis, five RCTs and 212 subjects). (Strength of statement: moderate).

### 2.3.4 | What is the effect of alveolar ridge preservation—Socket Grafting on the feasibility of implant placement without a second augmentation?

The feasibility of implant placement without simultaneous ancillary grafting is higher in sites that have received ARP-SG, but additional bone augmentation at the time of implant placement may be required after both ARP-SG and unassisted socket healing.

(Evidence Level 2: systematic review of RCTs without meta-analysis, five RCTs and 214 subjects) (Strength of statement: moderate).

### 2.3.5 | What is the performance of implants inserted at sites with alveolar ridge preservation?

Sites that received ARP-SG exhibit no differences compared with sites that underwent unassisted socket healing in terms of implant loss and implant success after a minimum of 12 months of functional loading with the final prosthesis.

(Evidence Level 2: systematic review of RCTs without meta-analysis, three RCTs and 95 subjects). (Strength of statement: moderate).

## 2.4 | Clinical recommendations

### 2.4.1 | When should clinicians consider ARP following tooth extraction?

Clinicians should consider ARP in clinical scenarios in which minimizing alveolar ridge dimensional changes is critical, such as

- Extraction sites in areas of aesthetic priority, both when an implant-supported and a tooth-retained (e.g. pontic site) restoration is planned.
- Extraction sites on which major ridge reduction is expected and may jeopardize implant placement, such as
  - Sites presenting a thin and/or substantially damaged buccal bone plate.
  - Posterior sites exhibiting limited ridge height post-extraction, which may lead to implant proximity to the maxillary sinus or nerve structures.
- In situations requiring that implant placement is significantly delayed after tooth extraction, such as, due to the young age of the patient.

### 2.4.2 | Which ARP treatment modality is most effective?

The application of a bone grafting material to fill the extraction socket is strongly recommended when ARP is indicated. Clinicians should also consider sealing the socket orifice using an autogenous or exogenous barrier material with the purpose of protecting the underlying bone

compartment and/or assist soft tissue healing. Socket sealing can be achieved either with or without primary soft tissue closure.

### 2.4.3 | How much healing time following ARP therapy is recommended prior to implant placement?

A minimum healing time that allows for sufficient bone formation, typically 3–4 months, is recommended. An extended healing time may be required on the basis of the phenotypic characteristics of the extraction site, the properties of the biomaterial(s) used and patient-specific systemic factors.

## 2.5 | Recommendations for future research

There is a need to conduct well-designed RCTs involving multiple arms that would allow for direct comparisons of different ARP modalities of therapy, including socket grafting and sealing materials, in different clinical scenarios (e.g. single- vs multi-rooted sites; damaged vs intact sockets). Relevant endpoints of interest that go beyond conventional linear clinical and radiographic assessments, such as bone and soft tissue volumetric dimensional changes, implant-related outcomes and PROMs, should be considered. Additionally, these studies should incorporate properly described, reproducible methods for assessment of outcomes of therapy that would allow for external validation, cost-benefit analyses and the performance of robust meta-analyses.

Future research should elucidate the influence of local and systemic patient-specific factors on the outcomes of ARP therapy (e.g. presence of concomitant pathology, soft tissue thickness, keratinized mucosa width, smoking, history of periodontitis and uncontrolled systemic conditions that may play a role in intra-oral bone and soft tissue healing).

## 3 | THE EFFECTIVENESS OF IMMEDIATE IMPLANT PLACEMENT FOR SINGLE TOOTH REPLACEMENT COMPARED TO DELAYED IMPLANT PLACEMENT: A SYSTEMATIC REVIEW AND META-ANALYSIS

### 3.1 | Preamble

The main goal and the primary outcome of this systematic review were to compare immediate implant placement for single tooth replacement to delayed implant placement in terms of implant survival (Cosyn et al., 2019).

Secondary outcomes included the following:

- Need for additional bone augmentation at the buccal aspect of the implant
- Wound-healing complications
- Marginal bone loss
- Probing depth and bleeding on probing

- Papillary recession
- Pink aesthetic score
- Patient-reported outcome measures
- Long-term complications.

The present systematic review includes eight investigations, comprising three RCTs and five CCTs. The study material included 512 patients (517 implants) with a follow-up ranging from 12 to 96 months.

Sufficient data were available to perform meta-analyses of the primary outcome and a limited number of secondary outcomes.

### 3.2 | External validity of the findings

The statements in this consensus report are primarily applicable to adults who require extraction of one single-rooted tooth with substantial socket wall integrity at the time of extraction in tooth-bound areas. The majority of the studies inclusion and exclusion criteria limited cases to sites without acute infection and with possibility to achieve primary stability of the immediately placed implant in the correct, prosthetically driven, position.

### 3.3 | Consensus statements

#### 3.3.1 | What clinical conditions have been included in studies comparing immediate and delayed implant placement?

Studies comparing immediate and delayed implant placement have used different inclusion and exclusion criteria, and these are important for understanding heterogeneity of results. A critical component is whether the buccal bone plate was essentially intact or not. Diverging results were observed in one multicenter RCT that included extraction sockets with up to 50% loss of the buccal bone plate and the other RCT that included essentially intact sockets. These observations may indicate that the level of buccal bone loss is a major prognostic factor for immediate implant placement.

(Evidence Level 4: Two RCTs designed for different purpose and showing heterogeneous results). (Strength of the statement: low due to limited and indirect evidence and heterogeneity).

#### 3.3.2 | How do immediate and delayed implant placement compare in terms of implant loss?

Immediate implant placement results in greater early implant loss compared with delayed implant placement (survival rate of 94.9% vs 98.9%; RR 0.96, 95% CI [0.93; 0.99],  $p = 0.02$ ).

(Evidence Level 1: systematic review with meta-analysis comprising three RCTs—135 subjects with 136 immediate implants and 131 subjects with 135 delayed implants—and five CCTs—120 subjects with 120 immediate implants and 126 subjects with 126 delayed implants)—(Strength of the statement: moderate due to heterogeneity and risk of bias).

#### 3.3.3 | How do immediate and delayed implant placement compare in terms of marginal bone loss?

Considering the baseline after loading (definitive crown installation), there are only two RCTs (110 patients with 111 immediate implants and 106 patients with 110 delayed implants) measuring marginal bone loss.

In both RCTs, bone augmentation was performed. In one RCT, immediate implants were placed in case of dehiscence up to 50% of the buccal bone wall resulting in 1.2 mm higher marginal bone loss for immediate implant placement. However, in the other RCT where an intact buccal bone wall was an inclusion criterion, no significant difference in marginal bone loss was observed.

(Evidence Level 2: One multicenter RCT and one RCT)—(Strength of the statement: low due to heterogeneity).

#### 3.3.4 | How do immediate and delayed implant placement compare in terms of probing depth?

Probing pocket depths were reported in one multicenter RCT. Probing pocket depths were greater at immediate implant compared with delayed placement (mean difference 0.8 mm, 95% CI: 0.4–1.2 mm) in this particular multicenter RCT with non-intact buccal bone wall.

(Evidence Level 2: One multicenter RCT, 124 patients)—(Strength of the statement: low due to single multicenter RCT).

#### 3.3.5 | How do immediate and delayed implant placement compare in terms of pink aesthetic score?

One multicenter RCT showed a trend towards lower pink aesthetic scores for immediate implant placement in cases with non-intact buccal bone wall.

(Evidence Level 2: One multicenter RCT and 124 patients)—(Strength of the statement: low due to single multicenter RCT).

### 3.4 | Clinical recommendations

#### 3.4.1 | Can immediate implant placement be recommended for single tooth replacement?

Clinicians considering immediate implant placement should be aware that it carries an additional risk of early implant loss (4% excess implant loss). Furthermore, at sites with non-intact alveolar sockets, inferior clinical, radiographic and patient-reported outcomes have been observed. No high-level comparative data are available for intact sockets.

#### 3.4.2 | When should immediate implant placement be avoided?

Immediate implant placement should be avoided at

- Extraction sites with severely damaged sockets (more than 50% loss of one or more walls).

- Extraction sites in which achievement of primary stability requires positioning of the implant in a prosthetically incorrect position.
- Extraction sites in which achievement of primary stability requires selecting an improper implant diameter.

### 3.4.3 | Should grafting be considered an integral component of immediate implant placement?

Grafting at immediate implant placement is an integral component of the procedure in the majority of cases.

### 3.4.4 | Which are the clinical indications of immediate implant placement?

Immediate implant placement may bring tangible patient benefits related to shorter treatment time and cost-efficiency. At this stage, indications should be limited to sites and patients that are perceived to be at low risk: non-aesthetic areas, intact alveoli, thick and flat periodontal phenotype.

### 3.5 | Recommendations for future research

There is a need for additional high-quality RCTs comparing immediate implant placement to delayed implant placement with CBCT analyses at different time points. Data should report on midfacial recession with the situation prior to tooth extraction as baseline. In these studies, the need for hard and soft tissue grafting should also be evaluated.

There is a need for PROMs, as these have been underreported in research so far. These should include morbidity and patient preference. There is a need for cost and efficiency analyses on both protocols.

## 4 | EFFECTIVENESS AND PERFORMANCE OF EARLY IMPLANT PLACEMENT FOR SINGLE TOOTH SITES OF ANTERIOR AREAS: A SYSTEMATIC REVIEW

### 4.1 | Preamble

Early implant placement has been advocated to address several shortcomings of conventional and immediate timing of insertion. These include (a) minimizing the potential negative effects of wound contamination from residual infection due to the cause of tooth loss; (b) limiting the potential negative effects resulting from hard and soft tissue healing after tooth extraction; and (c) decreasing treatment time with the potential to improve patient satisfaction (Graziani et al., 2019).

The systematic review identified data from six studies from five research groups reporting on a total of 140 implants in 140 subjects (107 for type II and 33 for type III). Paucity of data, lack of comparative studies of high-quality and study heterogeneity prevented executing of meta-analyses. The group expresses major concerns on the scientific methodology and publication strategies observed in some of the included manuscripts.

While both types of early implant placement seemed to perform well in these studies, significant issues in terms of study design and reporting, the pilot/proof of principle sample sizes and the absence of valid comparisons with other implant placement timing and approaches limit both the internal validity and the external validity of the results.

### 4.2 | External validity of the findings

The small number of documented and highly selected patients (140 subjects treated by five experienced surgeons) and the concerns with the design of the only RCT severely limit the generalizability of the results.

### 4.3 | Consensus statements

#### 4.3.1 | How do early and delayed implant placement compare in terms of implant loss?

There are no valid comparative data that have tested early and delayed implant placement. Reported clinical performance shows high levels of implant survival in small studies with up to 10 years follow-up.

(Evidence Level 4: One RCT at high risk of bias and probably invalid, one CCT and four retrospective or prospective case series, 140 subjects with 140 implants)—(Strength of the statement: low due to small sample, heterogeneity and risk of bias).

#### 4.3.2 | How do immediate and early implant placement compare in terms of implant loss?

There are no valid comparative data that have tested immediate and early implant placement. Reported clinical performance shows high levels of implant survival for both approaches.

(Evidence Level 5: expert opinion)—(Strength of the statement: low due to expert opinion in the absence of direct evidence).

#### 4.3.3 | What clinical conditions have been included in studies reporting on the performance of early implant placement?

Causes of tooth extraction/loss were generally not reported, and neither were the conditions of the residual bony walls of the alveolus. The assumption that the main indication for early implant placement is extraction at sites with compromised alveoli needs to be substantiated with additional research.

(Evidence Level 5: expert opinion)—(Strength of the statement: low due to expert opinion in the absence of direct evidence).

#### 4.3.4 | What is the performance of early implant placement in terms of peri-implant health parameters and aesthetics?

Few case series reporting on a limited number of patients have described good and stable outcomes with type 2 and type 3 placements. Their strength is the long-term follow-up. It is, however,

unclear how these results compare with those obtainable with other types of placement and what is their external applicability.

(Evidence Level 4: case series at different risk of bias)—(Strength of statement: low due to the absence of RCTs and limited number of documented cases).

#### 4.4 | Clinical recommendations

##### 4.4.1 | Is there evidence to recommend type 2 or type 3 implant placement in the anterior region?

Clinicians should be aware that the evidence on type 2 and type 3 implant placement is based on a restricted number of experienced clinicians (five surgeons) who have treated and followed a limited number of patients ( $N = 140$  implants/patients followed for at least 1 year, see also Gallucci et al., 2018). The limited available evidence shows good performance in the hands of few experienced clinicians and highly selected patients. It is, however, unclear if such data can be generalized and how they compare with those following immediate or delayed implant placement.

#### 4.5 | Recommendations for future research

Randomized clinical trials comparing different types of implant insertion are strongly advocated.

These trials should be designed taking into account not only the survival rate but also a broad array of clinically relevant outcomes ranging from aesthetic outcomes, dimensional hard and soft tissue changes, and patient-reported outcomes.

Trials should be carefully designed to evaluate the impact of significant confounders such as causes of tooth extraction/loss, the conditions of the alveolus, concomitant bone regenerative procedures and type of restorations.

## 5 | EFFICACY OF LATERAL BONE AUGMENTATION PERFORMED SIMULTANEOUSLY WITH DENTAL IMPLANT PLACEMENT: A SYSTEMATIC REVIEW AND META-ANALYSIS

### 5.1 | Preamble

The concept of placing dental implants in a prosthetically driven position often results in ridge deficiencies and the need for an additional bone augmentation procedure simultaneously with dental implant placement. Guided bone regeneration applying various biomaterials and barrier membranes is indicated in such clinical situations. Clinically, it is difficult to decide on a specific intervention given the vast variety of biomaterials and membranes available (Thoma, Bienz, Figuero, Jung, & Sanz-Martin, 2019).

Therefore, the present systematic review analysed the scientific evidence regarding the efficacy of lateral bone augmentation procedures in terms of defect resolution in cases of horizontal ridge deficiencies after implant placement.

The mean defect height resolution at re-entry (in mm and/or %) was considered as the primary outcome. Moreover, the influence of the type of membrane, the absence of treatment, the addition of a grafting material and the addition of a membrane on defect height resolution were evaluated.

Secondary outcomes included the following:

- Necessity for re-grafting
- Membrane exposure
- Implant survival
- Clinical, radiographic and volumetric outcomes of follow-up studies.

The systematic review includes 28 publications designed as RCTs ( $n = 16$ ), CCTs ( $n = 4$ ) or follow-up studies with an RCT design ( $n = 7$ ) or a CCT design ( $n = 1$ ). The 20 short-term studies reported on 819 patients (1,070 implants) with a follow-up range of 4–18 months. The eight follow-up studies reported on 174 patients (242 implants) with an observation period that had a range: 36–150 months. In all included studies, titanium dental implants with either a smooth or a moderately rough surfaced were used. Defect configurations and dimensions present at implant sites vary intra- and inter-individually. The selected literature did not provide sufficient information to determine these specific confounding factors related to the efficacy of the procedure.

Meta-analyses were performed for the primary outcome (defect height resolution) and whenever possible for secondary outcomes.

### 5.2 | External validity of the findings

The high number of included and, in general, well-designed RCTs with a large number of treated patients supports the use of guided bone regenerative procedures to reconstruct bone at dehiscence-type defects following implant placement. Generalizability is to some extent limited by a large heterogeneity in terms of materials used and the fact that no superiority of any material (combination) could be shown. Clinicians should therefore be careful when choosing a specific bone substitute and barrier membrane combination and check for documentation. It is also important to underline that this procedure has been generally documented for buccal dehiscences up to 8 mm in height.

### 5.3 | Consensus statements

#### 5.3.1 | What is the percentage of defect height resolution after bone augmentation procedures to cover exposed implant threads?

Defect height resolution at re-entry ranged from 56.4% to 97.1% at 4–6 months.

(Evidence Level 2: systematic review without meta-analysis of 20 publications [16 RCT's and four CCTs], of which nine had high, five



low and six unclear risk of bias reporting on 819 subjects with 1,070 implants)—(Strength of statement: moderate due to risk of bias).

### 5.3.2 | Is there a benefit to perform a bone augmentation procedure to cover exposed implant threads following implant placement?

One RCT demonstrated a significantly more favourable defect height resolution for sites with GBR compared to no treatment.

(Evidence Level 3: One RCT, 22 subjects and 28 implants with an unclear risk of bias)—(Strength of statement: low due to small evidence base).

### 5.3.3 | What is the most effective intervention to obtain defect resolution?

All barrier membranes and bone substitute material combinations tested obtained varying degrees of defect resolution.

(Evidence Level 1: systematic review with meta-analysis including 11 RCTs, 366 subjects and 464 implants)—(Strength of the statement: moderate, five RCTs were considered as low, three at unclear and three at high risk of bias).

### 5.3.4 | Is there a benefit of covering a biomaterial with a barrier membrane?

Bone augmentation was significantly more favourable when a biomaterial was covered with a membrane compared to a biomaterial alone.

(Evidence Level 1: systematic review with a meta-analysis, including two RCTs, 48 subjects and 52 implants)—(Strength of the statement: moderate due to unclear risk of bias).

### 5.3.5 | Is there a benefit supporting a barrier membrane with a biomaterial?

Defect height reduction was significantly more favourable when a biomaterial supported a membrane compared to a membrane alone.

(Evidence Level 4: One CCT, 19 subjects and 30 implants)—(Strength of the statement: low (single CCT at high risk of bias)).

### 5.3.6 | How frequently bone augmentation procedures yield to a 100% defect resolution and what is the necessity to re-augment?

The percentage of sites with a 100% defect resolution was reported in one CCT only and amounted to 76.7%.

The necessity to re-augment was inconsistently reported. No implant site needed re-augmentation in three RCTs, whereas in two studies, patients in need of re-augmentation were excluded.

(Evidence Level 2: systematic review without meta-analysis, five RCTs, one CCT, 165 subjects and 199 implants)—(Strength of the

statement: moderate since three studies were considered as low and one as unclear risk of bias. The remaining two studies were considered to have a high risk of bias).

### 5.3.7 | What is the most common complication?

The most common complication is unintentional membrane exposure with a mean rate of 22.7% (range: 16.8%–39.4%).

(Evidence Level 2: systematic review without meta-analysis of 16 RCT's, four CCTs, 820 subjects and 1069 implants)—(Strength of the statement: moderate).

Meta-analyses did not demonstrate any significant differences between different biomaterials and barrier membranes as well as their respective combinations.

(Evidence Level 2: systematic review without meta-analysis including 12 RCT's, one CCT, 502 subjects and 768 implants)—(Strength of the statement: moderate since five studies were considered as low and four as unclear risk of bias. The remaining four studies were considered to have a high risk of bias).

### 5.3.8 | What are the mid- and long-term outcomes of implants following bone augmentation at dehiscence and fenestration type defects?

The implant survival rate was not affected by the type of treatment (membrane, biomaterial, sites with exposed implant threads) and amounted to 95.0% (298 implants; 142 patients) with a follow-up range between 36 and 96 months. The range of biological complications was 0%–75% and the rate of peri-implantitis 12.8%.

(Evidence Level 2: systematic review without meta-analyses, including seven RCTs, one CCT, 142 subjects and 298 implants)—(Strength of the statement: moderate since one study was considered as low and four as unclear risk of bias. The remaining three studies were considered to have a high risk of bias).

## 5.4 | Clinical recommendations

### 5.4.1 | Is there a need to perform a bone augmentation procedure to cover exposed implant threads following implant placement?

The clinician should consider the use of a bone augmentation procedure to cover exposed implant threads after implant placement. Such a procedure renders a favourable defect height resolution.

### 5.4.2 | When should a clinician apply a bone augmentation procedure to cover exposed implant threads following implant placement?

The clinician should consider a bone augmentation procedure to cover exposed implant threads at different peri-implant defect configurations (documented up to a defect height of 8 mm).

A staged bone augmentation procedure might be considered if the implant cannot be placed in a prosthetically driven position, no primary stability can be obtained or in the presence of an unfavourable defect configuration.

#### 5.4.3 | Which intervention is recommended to treat peri-implant bone defects?

All barrier membranes and bone substitute material combinations tested obtained varying degrees of defect resolution (refer to SR). The clinician should combine a barrier membrane with a biomaterial. Only few membranes and biomaterials are well documented, and clinicians should be aware of the documentation before making a choice.

#### 5.4.4 | What complications should clinicians be aware of following bone augmentation procedures at peri-implant defects?

Clinicians should be aware of membrane exposure as the most common complication. The occurrence of such an adverse event results in a less favourable defect height resolution.

### 5.5 | Recommendations for future research

Further investigations should consider the following:

- The impact of bone augmentation at dehiscence or fenestration defects around dental implants on long-term peri-implant health
- Evaluating the need for bone augmentation at dehiscence or fenestration defects around dental implants
- Evaluating the threshold and the influence of defect dimensions and configurations on clinical, biological and radiographic outcomes
- Reporting on the success of the treatment (100% defect resolution) and on the impact of incomplete bone augmentation (e.g. <100% defect resolution and complications) on the efficacy of the intervention and on clinical, biological and radiographic outcomes
- Reporting on the effect of bone augmentation procedures on the hard and soft tissue contour, on the level of the mucosal margin and on aesthetic outcomes
- Including study patients in mid- to long-term follow-up examinations with standardized ways of reporting clinical, biological and radiographic outcomes as well as PROMs.

In general, for the planning of future studies related to bone augmentation procedures, it is recommended to report on specific inclusion criteria (e.g. ridge dimensions and configuration prior to implant placement; three-dimensional defect configuration after implant placement; and extent of bone augmentation), surgical protocols (e.g. bone- or prosthetically driven implant placement), early (e.g. wound dehiscences and barrier membrane exposures) and late (e.g. mucositis and peri-implantitis) complications.

## 6 | OVERALL CONSENSUS AND RECOMMENDATIONS

### 6.1 | Clinical recommendations

#### 6.1.1 | What is the best approach for transitioning from a failing tooth to a successful implant-supported tooth replacement prosthesis?

Based on strong pre-clinical evidence (Haugen, Lyngstadaas, Rossi, & Perale, 2019; Donos, Dereka, & Calciolari, 2019; Omar, Elgali, Dahlin, & Thomsen, 2019), five different approaches that have been documented to a different degree in clinical studies are illustrated in Figure 1. The evidence pertains mostly to single tooth replacement, and thus, extrapolation to other scenarios may not apply. Paucity of valid comparative studies does not allow for the construction of an evidence-based decision-making algorithm to select a specific approach that can be considered superior in individual clinical scenarios.

In the absence of solid evidence, clinicians have historically followed an empiric approach that has been supported by indirect pre-clinical and clinical evidence, mostly case series, to validate specific protocols. This process involves the consideration of several critical factors, such as the presence of local acute infection (purulence), the local anatomy in function of prosthetic needs, and the thickness and integrity of the remaining alveolar bone and the soft tissues (bone and soft tissue phenotype). Accumulated evidence from a growing number of randomized clinical trials has contributed to sharpen the assessment.

The following general considerations/recommendations can help in assisting the decision-making process:

- The presence of an acute local infection may render unpredictable outcomes following immediate implant placement or alveolar ridge preservation/ridge augmentation (ARP/RA). In such situations, early, delayed or late implant placement should be considered.
- The absence of primary stability upon implant placement and/or inability to place the implant in a favourable, restoratively driven position speaks against the indication of implant placement. In such situations, ARP/RA and delayed or late implant placement with simultaneous or staged alveolar ridge augmentation (implant site development) should be considered.
- A damaged alveolus, particularly in the presence of large buccal dehiscence or coronal fenestration, should be recognized as a clinical scenario in which the indication of immediate implant placement may be associated with a higher risk of achieving unfavourable therapeutic outcomes. In such situations, clinicians should consider an early implant placement protocol or ridge reconstruction at the time of tooth extraction and delayed or late implant placement.
- The presence of an intact alveolus and a thick periodontal phenotype represents a favourable scenario to indicate immediate

implant placement, particularly so in subjects with low aesthetic demands and/or in non-aesthetic areas.

- The presence of a thin periodontal phenotype and/or a high smile line in subjects with high aesthetic demands represents an unfavourable scenario for the indication of immediate or early implant placement. In such situations, ARP-SG and delayed or late implant placement should be considered. Consideration of the need and role of soft tissue augmentation in such cases was beyond the scope of this specific consensus.
- In subjects presenting uncontrolled local and/or systemic conditions that may alter the healing dynamics of extraction sockets (e.g. smoking, diabetes mellitus and severe autoimmune diseases), the indication of delayed or late implant placement should be considered over immediate or early implant placement. Clinicians must be aware that the outcomes of ARP/RA procedures may be negatively affected by the presence of such systemic conditions regardless of the timing of implant placement.

## 6.2 | Recommendations for future research

The group felt that, while considerable progress has been made since the last time the Workshop addressed the quality of research in implant dentistry (Tonetti & Palmer, 2012), several challenges persist.

Future research shall focus on providing appropriate comparative data assessing the efficacy, cost-effectiveness and patient acceptability of different approaches. Such studies shall be designed in order to enable the development of evidence-based decision-making algorithms and clinical recommendations. Emphasis on methodological issues in design, execution and reporting is required to continue to improve control of bias, external validity and integrity of research findings.

In order to sustain decisive improvements in the evidence base, the research community should focus on definition of a standard outcome data set, on clinically meaningful outcomes and on clinically relevant differences to appropriately power studies.

Greater emphasis on the evaluation and report of harm, adverse events and PROMs in all clinical studies is urgently required.

Given the perception that different procedures have dissimilar indications based on specific clinical situations, definition of a single standard of care to be used as the control group for comparative studies is problematic. Randomized controlled clinical trials will have to use different control groups based on the clinical situation being studied.

Valuable insight is to be gained from analytical studies aimed at assessing the significance of different prognostic factors, including the reason for tooth loss/extraction and/or the phenotypic characteristics of the residual alveolus. These studies will have to be high quality and provide adequate external validity.

In general, the evidence base in this field primarily emanates from single tooth replacement scenarios, and this has a profound impact on the applicability of the available data to multiple extractions and/or transitioning from a natural dentition to an

implant-retained prosthesis. While it is recognized that research on multiple extraction sites poses additional methodological and analytical challenges, it is important to expand the evidence base in this direction.

The population requiring tooth replacement is ageing and typically presents with a considerable set of relevant medical comorbidities and the long-term consumption of multiple medications. Ethically appropriate research on tooth replacement in special needs groups is urgently needed, as well.

## CONFLICT OF INTEREST

Workshop participants filed detailed disclosure of potential conflict of interest relevant to the workshop topics, and these are kept on file. Declared potential dual commitments included having received research funding, consultant fees and speaker fee from Biomet Zimmer, BioHorizons, Colgate, DentaId, Dentsply Implants, Dentium, Geass, Geistlich Pharma AG, Klockner, MIS Implants, Osteogenics Biomedical, Osteology Foundation, Procter & Gamble, Straumann, Sweden & Martina, Sunstar SA and VITA Zahnfabrik.

## ORCID

Maurizio S. Tonetti  <https://orcid.org/0000-0002-2743-0137>

Gustavo Avila-Ortiz  <https://orcid.org/0000-0002-5763-0201>

Jan Cosyn  <https://orcid.org/0000-0001-5042-2875>

Filippo Graziani  <https://orcid.org/0000-0001-8780-7306>

Phoebus Madianos  <https://orcid.org/0000-0002-5990-5723>

Ignacio Sanz-Martin  <https://orcid.org/0000-0001-7037-1163>

Daniel Thoma  <https://orcid.org/0000-0002-1764-7447>

Fabio Vignoletti  <https://orcid.org/0000-0002-4574-3671>

## REFERENCES

- Avila-Ortiz, G., Chambrone, L., & Vignoletti, F. (2019). Effect of alveolar ridge preservation interventions following tooth extraction: A systematic review and meta-analysis. *Journal of Clinical Periodontology*, 46(Suppl 21), 195–223.
- Cosyn, J., Lat, L., Seyssens, L., Doornewaard, R., Deschepper, E., & Vervaeke, S. (2019). The effectiveness of immediate implant placement for single tooth replacement compared to delayed implant placement: A systematic review and meta-analysis. *Journal of Clinical Periodontology*, 2019; 46(Suppl 21), 224–241.
- Donos, N., Dereka, X., & Calciolari, E. (2019). The use of bioactive factors to enhance bone regeneration. A narrative review. *Journal of Clinical Periodontology*, 46(Suppl 21), 124–161.
- Gallucci, G. O., Hamilton, A., Zhou, W., Buser, D., & Chen, S. (2018). Implant placement and loading protocols in partially edentulous patients: A systematic review. *Clinical Oral Implants Research*, 29(Suppl 16), 106–134.
- Graziani, F., Chappuis, V., Molina, A., Lazarin, R., Schmid, E., Chen, S., & Salvi, G. E. (2019). Effectiveness and clinical performance of early implant placement for the replacement of single teeth in anterior areas: A systematic review. *Journal of Clinical Periodontology*, 46(Suppl 21), 242–256.

- Guyatt, G., Oxman, A. D., Akl, E. A., Kunz, R., Vist, G., Brozek, J., ... Schunemann, H. J. (2011). GRADE guidelines: 1. Introduction- GRADE evidence profiles and summary of findings tables. *Journal of Clinical Epidemiology*, *64*, 383-394.
- Haugen, H. J., Lyngstadaas, S. P., Rossi, F., & Perale, G. (2019). Bone grafts: Which is the ideal biomaterial? *Journal of Clinical Periodontology*, *46*(Suppl 21), 92-102.
- Kassebaum, N. J., Bernabe, E., Dahiya, M., Bhandari, B., Murray, C. J., & Marcenes, W. (2014). Global burden of severe tooth loss: A systematic review and meta-analysis. *Journal of Dental Research*, *93*, 20s-28s.
- Omar, O., Elgali, I., Dahlin, C., & Thomsen, P. (2019). Barrier membranes: More than the barrier effect? *Journal of Clinical Periodontology*, *46*(Suppl 21), 103-123.
- Sculean, A., Stavropoulos, A., & Bosshardt, D. D. (2019). Self-regenerative capacity of intra-oral bone defects. *Journal of Clinical Periodontology*, *46*(Suppl. 21):70-81.
- Thoma, D. S., Bienz, S. P., Figuero, E., Jung, R. E., & Sanz-Martin, I. (2019). Efficacy of lateral bone augmentation performed simultaneously with dental implant placement. A systematic review and meta-analysis. *Journal of Clinical Periodontology*, *46*(Suppl 21), 257-276.
- Tonetti, M. S., Jepsen, S., & Working Group 2 of the European Workshop On Periodontology. (2014). Clinical efficacy of periodontal plastic surgery procedures: Consensus report of Group 2 of the 10th European Workshop on Periodontology. *Journal of Clinical Periodontology*, *41*(Suppl 15), S36-S43.
- Tonetti, M., & Palmer, R. (2012). Clinical research in implant dentistry: Study design, reporting and outcome measurements: Consensus report of Working Group 2 of the VIII European Workshop on Periodontology. *Journal of Clinical Periodontology*, *39*(Suppl 12), 73-80.
- van der Weijden, F., Dell'Acqua, F., & Slot, D. E. (2009). Alveolar bone dimensional changes of post-extraction sockets in humans: A systematic review. *Journal of Clinical Periodontology*, *36*, 1048-1058.

**How to cite this article:** Tonetti MS, Jung RE, Avila-Ortiz G, et al. Management of the extraction socket and timing of implant placement: Consensus report and clinical recommendations of group 3 of the XV European Workshop in Periodontology. *J Clin Periodontol*. 2019;46(Suppl. 21):183-194. <https://doi.org/10.1111/jcpe.13131>